

*M de Araújo Nobre*  
*N Cintra*  
*P Maló*

## Peri-implant maintenance of immediate function implants: a pilot study comparing hyaluronic acid and chlorhexidine

### Authors' affiliations:

*Miguel de Araújo Nobre*, Private Practice, Department of Oral Hygiene, Department of Clinical Research, Clínica Maló, Lisbon, Portugal

*Nuno Cintra*, Private Practice, Department of Oral Surgery, Clínica Maló, Lisbon, Portugal

*Paulo Maló*, Private Practice, Department of Implantology and Prosthodontics, Clínica Maló, Lisbon, Portugal

### Correspondence to:

*Miguel de Araújo Nobre*  
 Clínica Maló  
 Avenida Dos Combatentes  
 43, 9C, Edifício Green Park  
 1600-042 Lisbon  
 Portugal  
 Tel.: +351 21 722 81 00  
 Fax: +351 21 726 69 65  
 E-mail: mignobre@gmail.com;  
 mnobre@clinicamalo.pt

### Dates:

Accepted 15 February 2007

### To cite this article:

*Int J Dent Hygiene* 5, 2007; 87–94  
 de Araújo Nobre M, Cintra N, Maló P. Peri-implant maintenance of immediate function implants: a pilot study comparing hyaluronic acid and chlorhexidine.

© 2007 The Authors.

Journal compilation © 2007 Blackwell Munksgaard

**Abstract:** *Introduction:* In implants, maintenance assumes an important role. The role of chlorhexidine (CHX) is well known in maintenance, while only limited evidence exists on the practical use of hyaluronic acid (HA). The objective of this study was to compare the health status of the peri-implant complex (hard and soft tissues surrounding the implant) during the healing period of immediate function implants, using HA or CHX gels in the patient's maintenance protocol. *Study population and methodology:* Thirty complete edentulous patients, with four immediate function Brånemark System implants placed in the mandible (total of 120 implants), were randomly assigned to two groups (HA and CHX) using only these two chemicals in their daily implant self-care. Both groups were followed up for 6 months, with clinical observations on the 10th day, 2 months, 4 months and 6 months post-surgically. *Results:* During the course of the study, HA and CHX produced good results in maintaining a healthy peri-implant complex in immediate function implants for complete rehabilitations in the edentulous mandible. Statistically significant differences were found in favour of the HA group in the modified bleeding index on the second observation ( $P = 0.003$ ). The difference was more marked in the axial implants placed in the fifth sextant ( $P = 0.05$ ). Correlation coefficient between plaque and bleeding index revealed a potentially better result for CHX at 6 months.

*Conclusion:* The findings point out the importance of a maintenance protocol in immediate function implants. Both chemicals are valid tools for implant maintenance. The authors suggest that it might be advantageous to

administer HA in the first 2 months and CHX between 2 and 6 months.

**Key words:** axial implants; chlorhexidine; gel; hyaluronic acid; immediate function; maintenance; oral hygiene; oral implants; tilted implants

## Introduction

In recent years more studies have been dealing with the concept of immediate function in implantology, which consists of the placement of the implant, abutment and crown on the same surgical step (1).

The maintenance phase of prosthetic rehabilitations with immediate function implants, assumes a role as important as the surgical phase, influencing the implants' success rate (2, 3). The patient's oral hygiene has a significant impact on bone stability around osseointegrated implants, and even in complete edentulous patients, a bad oral hygiene relates to an increased bone loss (4). Moreover, still the best way of treating peri-implant pathologies is to prevent it (5, 6).

Hyaluronic acid (HA) is described as a natural organic substance, with physiological therapy activity, main component of the extracellular matrix of many tissues such as the skin, synovial joints and periodontal tissues (7).

Hyaluronic acid possesses physiological and structural functions in the tissues, including cellular and extracellular interactions, interactions with growth factors and regulation of the osmotic pressure and tissue lubrication, which helps in maintaining the tissues' structural and homeostatic integrity (8, 9).

Hyaluronic acid has a multifunctional role in healing cronical lesions, including those that are observed in periodontal disease (10). In non-surgical treatment of periodontal disease, the administration of high molecular weight HA proved to be effective in inducing tissue repair and healing in patients with inflammatory gingivitis and surgical wounds (7, 11–13). Still, references in the literature for long-term use of HA in maintenance are sparse.

Chlorhexidine (CHX) represents the most efficient molecule of all antiseptics used in the oral cavity (14, 15), with its efficacy attributed to: the bactericide effect (the lethal effect of CHX is related to extensive intracellular damage inflicted in bacteria), the bacteriostatic effect (which becomes lethal with the increasing concentration, causing precipitation or coagulation of bacteria cytoplasm), its substantive properties in the

oral cavity, being its antimicrobial effect attributed to its dicationic structure (16–18).

The aim of this randomized clinical controlled trial was to compare the health status of the peri-implant complex (hard and soft tissues surrounding the implants) in two groups of patients: (1) using 0.2% HA gel for daily implant self-care; (2) using 0.2% CHX gel for daily implant self-care; testing the hypothesis that the health status of peri-implant complex during the healing phase of immediate function implants would follow the same distribution for the implants in HA and CHX groups, tested by comparing the clinical and radiological evaluation parameters (Table 1).

## Study population and methodology

This study was performed between January 2004 and December 2004 at a private practice, Clinica Maló in Lisbon, Portugal. The implants were placed and monitored by the same team.

The participants for this study were selected according to an inclusion criterion that consisted of patients submitted to a complete fixed prosthetic rehabilitation of the mandible with four immediate function implants: two anterior implants placed in axial position and two posterior implants tilted up to 40° distally, placed bilateral and immediately in front of the mental foramens (19). The implants consisted of Brånemark System™ Mk III Ti-Unite Ø 4 × 15 mm (Nobel Biocare AB™, Gothenburg, Sweden). The prostheses were connected to the implants on the same day as the implant surgery, and care was taken to leave enough space in the mucosa–prosthesis interface, so to facilitate the patients' oral hygiene during the healing period. Post-surgical medication included: antibiotics (amoxicillin 875 mg + clavulanic acid 125 mg; Labesfal, Campo de Besteiros, Portugal) that were given 1 h prior to surgery and daily for 6 days thereafter. Cortisone medication (prednisone; Meticorten® Schering-Plough Farma, Lda, Agualva-Cacém, Portugal, 5 mg) was given daily in a regression mode (15–5 mg) from the day of surgery until 4 days postoperatively. Anti-inflammatory medication (ibuprofen, 600 mg;

**Table 1. Clinical and radiological evaluation parameters for the two groups**

Observations	Group HA			Group CHX			P-value
	Mean	SD	Median	Mean	SD	Median	
10th day observation							
mPII	1.38	0.73	1.75	1.45	0.88	1.5	0.597
mBI	0.27	0.36	0.25	0.52	0.53	0.50	0.131
2 months observation							
mPII	1.03	0.71	1	1.6	0.55	1.75	0.061
mBI	0.10	0.13	0	0.37	0.23	0.25	0.003*
PPD	1.7	0.62	2	1.8	0.56	2	0.502
4 months observation							
mPII	1.4	0.66	1.5	1.42	0.52	1.5	0.966
mBI	0.18	0.20	0.25	0.23	0.28	0.25	0.612
PPD	1.6	0.63	2	1.7	0.68	2	0.638
6 months observation							
mPII	0.93	1.03	1	1.4	0.63	1	0.071
mBI	1.07	0.70	1	0.87	0.64	1	0.417
PPD	1.6	0.72	2	1.7	0.64	2	0.625

\*Statistically significant.

Ratiopharm, Lda, Carnaxide, Portugal) was administered for 4 days postoperatively starting on day 4. Analgesics (clonixine; Clonix<sup>®</sup>, Janssen-Cilag Farmaceutica, Lda, Barcarena, Portugal, 300 mg,) were given on the day of surgery and postoperatively for the first 3 days if needed. Antacid medication (Omeprazole, 20 mg; Sandoz, Lisbon, Portugal) was given on the day of surgery and daily for 6 days postoperatively.

Other inclusion criteria consisted of the participants having to be present in the maintenance appointments; and all participants needed to be followed up for 6 months.

As exclusion criteria, those generally used when performing implant treatment were followed (20). Further, patients with the following conditions were excluded: need of bone grafting procedures, diabetes, immunodeficiency pathology, smoker, bruxism, stress situation (socially or professionally), emotional instability, unrealistic aesthetic demands, patients with generalized oral inflammation/infection, diagnosis of an oral pathology that would impede continuing the study, the use of antibiotics beyond the first 10 days after surgery and patients who did not complete the follow-up.

Both patients and the investigators were blinded regarding the products used for implant maintenance during the course of the study.

### Clinical evaluation parameters

The clinical evaluation parameters performed for monitoring the peri-implant complex health status consisted of: modified plaque index (mPII) (21), modified bleeding index (mBI) (21), probing pocket depth (PPD) in millimetres (22), assessed with

a calibrated Kerr-Hawe<sup>®</sup> Perio-probe (Hawe-Neos, Bioggio, Switzerland), suppuration (Sup), observed after applying finger pressure to the peri-implant complex and registered as present or absent (23), clinical implant mobility (mob) accessed manually, by applying lateral movements to the implant and registered as present or absent (22). The investigators were calibrated regarding the measurements of clinical parameters.

### Radiological evaluation parameters

The radiological evaluation consisted of observations of periapical X-rays registering radiolucent areas around the implant as present or absent (22). The radiographs were taken at the third observation (around 4 months), using a Trophy<sup>®</sup> X-ray (Kodak, Rochester, NY, USA); Kodak<sup>®</sup> pellicles and anterior/posterior film holders Superbite Hawe-Neos<sup>®</sup> (Hawe-Neos), to secure an orthognatic position of the film. A calibration was performed regarding the measurements of radiological parameters.

### Methodology for data collection

The patients were randomly assigned to each group, according to a random numbers table collected at <http://random.org/sform.html>.

The data were registered in an individualized form, containing the clinical and radiological parameters assessed for each patient.

Figure 1 illustrates the clinical sequence of the study. One day before surgery (day -1), the study design was explained to patients and a written consent was requested. On the day of surgery, an oral hygiene clinical appointment was performed on the patient, where besides the prophylactic procedures, oral hygiene instructions were given about the tooth brush (7/100<sup>®</sup>; Pierre-Fabre Dermo-Cosmétique, Lda, Portugal) and the gel used: 0.2% HA gel (Gengigel<sup>®</sup>; Ricerfarma rfa, Italy) for group 1, or 0.2% CHX gel (Elugel<sup>®</sup>; Pierre-Fabre Dermo-Cosmétique Lda, Portugal) for group 2. The patients were instructed to refrain from using any other mechanical or chemical means of removing dental plaque besides the toothbrush and the HA or CHX gel.

On day 10 post-surgically, the prosthesis was removed, followed by suture removal and clinical indexes assessment. The patients were re-instructed about their self-care, and another tooth brush was delivered (15/100<sup>®</sup>; Pierre-Fabre Dermo-Cosmétique, Lda, Portugal) to substitute the one delivered at day -1. At 2, 4 and 6 months post-surgically, the clinical sequence was repeated, adding a peri-apical X-ray at 4 months for monitoring radiolucent areas around the implant. In between the maintenance appointments, the patients main-

<b>Professional procedures</b>	Study information; written informed consent     	Oral Hygiene clinical appointment; oral hygiene instructions; surgery   	Suture removal; oral hygiene clinical appointment; oral hygiene instructions; new toothbrush   	Oral hygiene clinical appointment; oral hygiene instructions   	Oral hygiene clinical appointment; oral hygiene instructions   	Final diagnosis         
<b>Diagnostic methods</b>	         	         	mPII; Sup; mBI; Mob     	mPII; Sup; mBI; Mob; PPD     	mPII; Sup; mBI; Mob; PPD; Periapical X-ray     	mPII; Sup; mBI; Mob; PPD     
<b>Time elapsed</b>	Day -1-----Day 0-----		Day 10-----	Month 2-----	Month 4-----	Month 6
<b>Patient procedures</b>	Day of the surgery; beginning of gel therapy		Gel therapy with HA or CHX	Gel therapy with HA or CHX	Gel therapy with HA or CHX	Gel therapy with HA or CHX

Fig. 1. Clinical chronology regarding professional procedure, diagnostic methods and patient procedures in the study.

tained their rehabilitation using just the toothbrush and either the HA or CHX gels.

**Statistical analysis**

Descriptive and inferential statistics for all clinical and radiological parameters were performed, to evaluate the results of the two therapies, using a significance level of 5%.

Two statistical approaches were used. The first, on patient level, analysed 30 participants, divided in two groups of 15. The second approach (at implant level), analysed the mBI at 2 months, to compare data from the position of the implant, comparing each of the four implants within the two groups, with a total of eight groups with 15 implants.

Spearman correlation coefficients were used to establish the degree of association between dental plaque (mPII) and peri-implant mucosal bleeding (mBI).

**Results**

The sample was represented by 30 individuals, of both genders with ages between 44 and 80 years (mean 58.6 ± 9.51). Age did not differ between the two groups ( $P = 0.346 > 0.05$ ) (Mann–Whitney test).

A total of 120 implants were placed in these 30 patients, four on each patient, and all patients were followed up for the proposed time in this study.

**Clinical evaluation parameters on patient level**

**mPII**

A median of 1.5 was registered in the first three observations, while a median of 1 was registered in the fourth observation, meaning that plaque was always present around the implants when tested.

The difference in mPII between the two groups was found not to be statistically significant in any of the four observations ( $P > 0.05$ ).

**mBI**

On a general level, the mBI values were very low, with a median of 0 in the first three observations and 1 in the fourth observation. A statistically significant difference was found between the two groups, in the mBI of the second observation (2 months post-surgically) in favour of the hyaluronic acid gel ( $P = 0.003 < 0.05$ ) (Kruskall–Wallis test).

**PPD**

The mean PPD was 2 mm for both groups. The difference was found not statistically significant between the two groups at any observation ( $P > 0.05$ ).

**Mob**

No differences were found between the two groups, as no implant was found mobile when clinically tested.

**Sup**

No differences were found between the two groups, as no implant presented suppuration when clinically tested.

**Radiological evaluation parameter**

No differences were found between the two groups, as no implant presented radiolucency around it when radiologically tested.

**Clinical evaluation parameters on implant level**

This approach was applied to the mBI on the second observation period, to assess the local effect of the two chemicals in test (Table 2).

On implant level, a statistically significant difference in favour of the HA group ( $P = 0.050$ ) (Kruskall–Wallis test) was observed, meaning that the effect was found to be more pronounced in the anterior implants localized on the third and fourth quadrant.

**Correlation coefficient between MPII and MBI**

The Spearman correlation coefficient was analysed for the two groups in the three observations, with the objective of testing the cause–effect relationship between dental plaque (assessed through the mPII index) and bleeding of the peri-implant mucosa (assessed through the mBI index) (Fig. 2).

Regarding the HA group, the coefficient of correlation between mPII and mBI came from a negative correlation in the first observation to a strong positive and statistically significant correlation in the fourth observation ( $r = 0.716$ ;

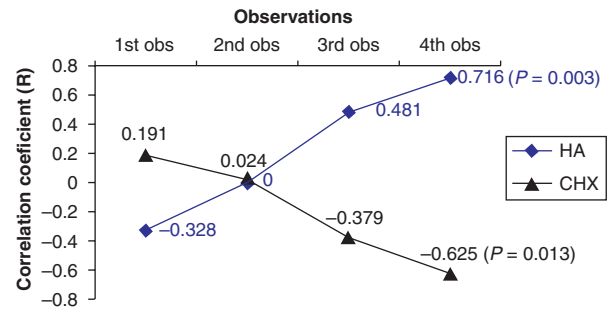


Fig. 2. Correlation coefficient between the modified plaque index (mPII) and modified bleeding index (mBI) at the patient level. Note the inverse relationship between hyaluronic acid and chlorhexidine groups.

$P = 0.003$ ). Regarding CHX, this group’s coefficient of correlation between mPII and mBI came from a positive correlation in the first observation to a negative strong and statistically significant correlation in the fourth observation ( $r = -0.625$ ;  $P = 0.013$ ).

**Discussion**

Generally, HA and CHX produced very positive results in the maintenance of complete edentulous mandible rehabilitations with fixed prostheses supported by immediate function implants.

Maintenance is key if one aims at implant success, having been observed in this study the positive effects of a maintenance strategy for implants, this way accounting for good clinical outcomes up to 6 months post-surgically. These results can be supported in the literature, where oral hygiene’s significant impact on bone stability around osseointegrated implants was verified (2, 3); moreover, in complete edentulous patients rehabilitated prosthetically, an insufficient oral hygiene was related to a higher bone loss (4).

The gel as a means of chemical administration has proven a valid mechanism in our study, this fact having been previously observed in periodontal treatment (24). The mechanism can be

Table 2. Modified bleeding index in the second observation for the two groups

	Group HA			Group CHX			P-value
	Mean	SD	Median	Mean	SD	Median	
mBI tilted 3rd quadrant	0.07	0.26	0	0.27	0.59	0	0.276
mBI axial 3rd quadrant	0.13	0.35	0	0.53	0.52	1	0.05*
mBI tilted 4th quadrant	0	0	0	0.27	0.46	0	0.369
mBI axial 4th quadrant	0.20	0.41	0	0.47	0.52	0	0.05*

\*Statistically significant.

Comparative evaluation at implant level: tilted implant of the 3rd quadrant; axial implant of the 3rd quadrant; tilted implant on the 4th quadrant; axial implant on the 4th quadrant.

explained through the gel's specific action, that when combined with mechanical stimulation of the tissues (through brushing) (25–27), it allows to achieve good results, being superior to the ones obtained with the mouthwash therapy (28).

In this study, the main comparison between the peri-implant complex of the two groups was the relation between the mPII and the mBI, in which the key to maintenance is found, as both plaque and bleeding indexes are reliable parameters for evaluating the patient's home care and the health of the peri-implant mucosa respectively (22). During the course of the study, the plaque indexes never differed significantly between both groups, suggesting that oral hygiene practice also did not differ significantly among the participants.

The mPII levels reflected that dental plaque was always present around the implants, being possible to be observed by the naked eye. This presence of dental plaque meant that the patients did not achieve high levels of dental hygiene self-care. This fact could be explained by the patient's lack of compliance or ability to perform self-care (29) or by the fact that the patient's only maintenance tool was the tooth brush, without other supportive mechanical means of dental plaque removal.

The presence of dental plaque represents an aetiological factor for the development of peri-implant disease (30). In our study, despite the plaque was always present (establishing good conditions for the development of peri-implant pathology), the bleeding index was extremely low, indicating excellent peri-implant health and suggesting that the pathological effect of dental plaque was inhibited.

These results were also observed in the literature, as several authors observed an improvement in gingival patterns for HA (12) as well as for CHX therapy. However, the gingival patterns' improvement observed for CHX therapy, occurred along with a constant dental plaque index level, or an increase of supra-gingival calculus (31, 32), fact that was also observed in our study.

For HA, the possible mechanisms for these results include the bacteriostatic effect patterns (observed *in vitro*) on microorganisms such as *Porphyromonas gingivalis*, *Actinobacillus actinomycetemcomitans*, *Staphylococcus aureus*, leading to a decrease in the risk of post-surgical infection and promoting a more predictable regeneration (33).

As for CHX, the possible mechanisms for the reduction of bleeding indexes include: a possible reduction of pathogenic bacteria in dental plaque and/or a reduction of plaque metabolism (31); the CHX bactericide and substantive effect (34); the CHX bacteriostatic effect [by reducing the amount of active cultures of Gram positive micro-organisms (*S. aureus*) and Gram negative (*Porphyromona/Prevotella* spp. and *Fusobacterium*

spp.) after 3 months (35)]; the CHX particular effect on the neutralization of pathogenic agents such as *S. aureus*, *P. gingivalis* and *Prevotella intermedia* (observed *in vitro*) (36); or by a decrease in the oedema, vasodilatation or presence of pro-inflammatory cytokine interleukine-8 (based on a inflammation model) (37).

In our study, however, despite having proved that the use of these chemicals induced an inhibition of the dental plaque's pathological effect over peri-implant tissues (due to the presence of dental plaque and the extremely low bleeding index), it was not possible to determine with assurance the mechanism of inhibition, and because no microbiological tests were performed, this question remains open.

The statistical significant difference favourable to the HA on the MBI in the second observation (around 2 months post-surgically) rejects the hypothesis that the health status of the peri-implant complex during the healing phase of immediate function implants follows the same distribution for the HA and CHX groups. Furthermore, regarding the implant level analysis, a statistically significant difference was found in favour of HA localized on the anterior implants (the fifth sextant axial implants). These differences were observed at a time interval in which the soft tissue finalizes its healing, and therefore, the HA acted as a healing agent. This healing effect is found to be related to the modulation and acceleration of the host response by the HA, as a consequence of its numerous biochemical and biophysical properties, its non-toxic effect and its biocompatibility (38).

Complementing the results, there is the correlation between mPII and mBI (Fig. 1). In this evaluation, we can observe a pattern in the association between mPII and mBI, where in HA group came from a negative correlation in the first observations to a strong positive and statistically significant correlation in the fourth observation ( $r = 0.716$ ;  $P = 0.003$ ); while an opposite correlation occurred for the CHX group, coming from a positive correlation in the first observation to a negative strong and statistically significant correlation on the fourth observation ( $r = -0.625$ ;  $P = 0.013$ ), and this way demonstrating a tendency to potentiate the CHX effect in detrimental to HA on a long term. These results find parallel in the literature, where significant positive changes in gingival health are reported, as for the increasing of supra-gingival calculus, in patients submitted to a CHX therapy for 6 months (22, 39).

Taking into consideration these results and fragilities of this study, the authors suggest that it might be advantageous to administrate HA in the first 2 months post-surgically, as this time frame represents a healing period; while CHX administration should be used for the remaining period (between 2 and

6 months post-surgically), as this time frame represents an exclusive maintenance period.

So, more and larger randomized controlled trials are needed to explore the effect of these agents over implants on both clinical and microbiological levels, generating efficient maintenance protocols, with the objective of increasing the success in implantology.

## Acknowledgements

This study was performed during the preparation of an academic paper. No funding was undertaken during the completion of this study.

## References

- Maló P, Rangert B, Dvarsater L. Immediate function of Brånemark implants in the esthetic zone – a retrospective clinical study with 6 months to 4 years of follow-up. *Clin Impl Dent Relat Res* 2000; **2**: 138–146.
- Bauman GR, Mills M, Rapley JW, Hallmon WW. Implant maintenance: debridement and peri-implant home care. *Compendium* 1991; **12**: 644, 646, 648 passim.
- Hillenburg KL, Kosinski TF, Mentag PJ. Control of peri-implant inflammation. *Pract Periodontics Aesthet Dent* 1991; **3**: 11–16.
- Quirynen M, De Soete M, Van Sreenberghe D. Infectious risks for oral implants: a review of the literature. *Clin Oral Impl Res* 2002; **13**: 1–19.
- Jovanovic S. Peri-implant tissue response to pathological insults. *Adv Dent Res* 1999; **13**: 82–86.
- Clarizio LF. Peri-implant infections. *Atlas Oral Maxillofac Surg Clin North Am* 2000; **8**: 35–54.
- Rabasseda X. The role of hyaluronic acid in the management of periodontal disease. *Drugs Today* 2000; **36**: 1–20.
- Chen WY, Abatangelo G. Functions of hyaluronan in wound repair. *Wound Repair Regen* 1999; **7**: 79–89.
- Moseley R, Waddington RJ, Embery G. Hyaluronan and its potential role in periodontal healing. *Dental Update* 2002; **29**: 2–9.
- Mesa FL, Aneiros J, Cabrera A et al. Antiproliferative effect of topical hyaluronic acid gel. Study in gingival biopsies of patients with periodontal disease. *Histol Histopathol* 2002; **17**: 747–753.
- Vangelisti R, Pagnacco O, Erra C. Hyaluronic acid in the topical treatment of gingival inflammations: preliminary clinical trial. *Transl Attualità Terapeutica Int* 1997; **3**: 1–7.
- Jentsch H, Pomowski R, Kundt G, Gocke R. Treatment of gingivitis with hyaluronan. *J Clin Periodontol* 2003; **30**: 159–164.
- Pagnacco O, Vangelisti R, Erra C, Poma A. Double-blind clinical trial vs. Placebo of a new sodium-hyaluronate-based gingival gel. *Transl Attualità Terapeutica Int* 1997; **4**: 1–12.
- Kamagate A, Kone D, Coulibaly NT, Brou E, Sixou M. In vitro study of chlorhexidine resistance in subgingival bacteria. *Odontostomatol Trop* 2002; **25**: 5–10.
- Eren K, Ozmeriço N, Sardas S. Monitoring of buccal epithelial cells by alkaline comet assay (single cell gel electrophoresis technique) in cytogenetic evaluation of chlorhexidine. *Clin Oral Inv* 2002; **6**: 150–154.
- Hennessey TD. Antibacterial properties of hibitane. *J Perio Res* 1977; **4**: 36–48.
- Salas Campos L, Gomez FO, Villar MH, Martin RB. Antiseptic agents: chlorhexidine. *Rev Enferm* 2000; **23**: 637–640.
- Moshrefi A. Chlorhexidine. *J West Soc Periodontol* 2002; **50**: 5–9.
- Maló P, Rangert B, Nobre M. ‘All-on-Four’ immediate-function concept with Branemark system implantes for completely edentulous mandibles – a retrospective study. *Clin Impl Dent Relat Res* 2003; **5** (Suppl. 1): 2–10.
- Lekholm U. Surgical considerations and possible shortcomings of host sites. *J Prosthet Dent* 1998; **79**: 43–48.
- Mombelli A, Van Oosten MAC, Shurch E, Lang NP. The microbiota associated with successful or failing osseointegrated titanium implants. *Oral Microbiol Immunol* 1987; **2**: 145–151.
- Buser D, Weber HP, Lang NP. Tissue integration of non-submerged implants 1-year results of a prospective study with 100 ITI hollow-cylinder and hollow-screw implants. *Clin Oral Impl Res* 1990; **1**: 33–40.
- Maló P. Clinical applications of immediate function implants on completely edentulous maxilla with full arch fixed bridge. In: Chiappasco M, ed. *Osteointegrazione e Carico Immediata. Fondamenti Biologici e Applicazioni Cliniche*. Milano, Itália, Masson, Spa, 2002, 60–102.
- John V, Phillips G. Locally delivered antimicrobials in periodontal treatment. *J Indiana Dent Assoc* 2002; **81**: 10–14.
- Keltjens HMAM, Van Der Hoeven JS, Hendriks JCM. Effects of chlorhexidine gel on periodontal health of abutment teeth in patients with overdentures. *Clin Oral Impl Res* 1991; **2**: 71–74.
- Keltjens HMAM, Creugers TJ, Schaeken MJM, Van Der Hoeven JS. Effects of chlorhexidine-containing gel and varnish on abutment teeth in patients with overdentures. *J Dental Res* 1992; **71**: 1582–1586.
- Porras R, Anderson GB, Cafesse R, Narendran S, Trejo PM. Clinical response to 2 different therapeutic regimens to treat peri-implant mucositis. *J Periodontol* 2002; **73**: 1118–1125.
- Pai MR, Acharya LD, Udupa N. The effect of two different dental gels and mouthwash on plaque and gingival scores: a six-week clinical study. *Int Dental J* 2004; **54**: 219–223.
- Hendrikx MJ, Kramer JE, De Baat C. Overdentures covering natural roots. The use of chlorhexidine gel. *Ned Tijdschr Tandheelkd* 2000; **107**: 94–96.
- Pontoriero R, Tonelli MP, Carneale G, Mombelli A, Nyman SR, Lang NP. Experimentally induced peri-implant mucositis. A clinical study in humans. *Clin Oral Impl Res* 1994; **5**: 254–259.
- Felo A, Shibly O, Ciancio SG, Lauciello FR, Ho A. Effects of subgingival chlorhexidine irrigation on peri-implant maintenance. *Am J Dent* 1997; **10**: 107–110.
- Lang NP, Hase JC, Grassi M et al. Plaque formation and gingivitis after supervised mouthrinsing with 0.2% delmopinol hydrochloride, 0.2% chlorhexidine digluconate and placebo for 6 months. *Oral Dis* 1998; **4**: 105–113.
- Pirnazar P, Wolinsky L, Nachnani S, Haake S, Pilloni A, Bernard GW. Bacteriostatic effects of hyaluronic acid. *J Periodontol* 1999; **70**: 370–374.
- Vaahntoniemi LH, Raisanen S, Stenfors LE. Effect of chlorhexidine and toothbrushing on the presence of bacteria on gingival and buccal epithelial cells. *Oral Microbiol Immunol* 1994; **9**: 315–317.
- Hase JC, Edwardsson S, Rundegren J, Attstrom R, Kelty E. 6-month use of 0.2% delmopinol hydrochloride in comparison with

- 0.2% chlorhexidine digluconate and placebo. *J Clin Perio* 1998; **25**: 841–849.
- 36 Vianna ME, Gomes BP, Berber VB, Zaia AA, Ferraz CC, Souza-Filho FJ. In vitro evaluation of the antimicrobial activity of chlorhexidine and sodium hypochlorite. *Oral Surg Oral Med Oral Pat* 2004; **97**: 79–84.
- 37 Boisnic S, Ben Slama L, Branchet-Gumila MC, D'Arros G. Contribution of parodium gel in an experimental model of human gingival inflammation. *Rev Stomatol Chir Maxillofac* 2003; **104**: 201–205.
- 38 Moseley R, Waddington RJ, Embery G. Hyaluronan and its potential role in periodontal healing. *Dental Update* 2002; **29**: 144–148.
- 39 Bretz WA, Valente MI, Djahjah C, do Valle EV, Weyant RJ, Nor JE. Chlorhexidine varnishes prevent gingivitis in adolescents. *ASDC J Den Child* 2000; **67**: 399–402.